

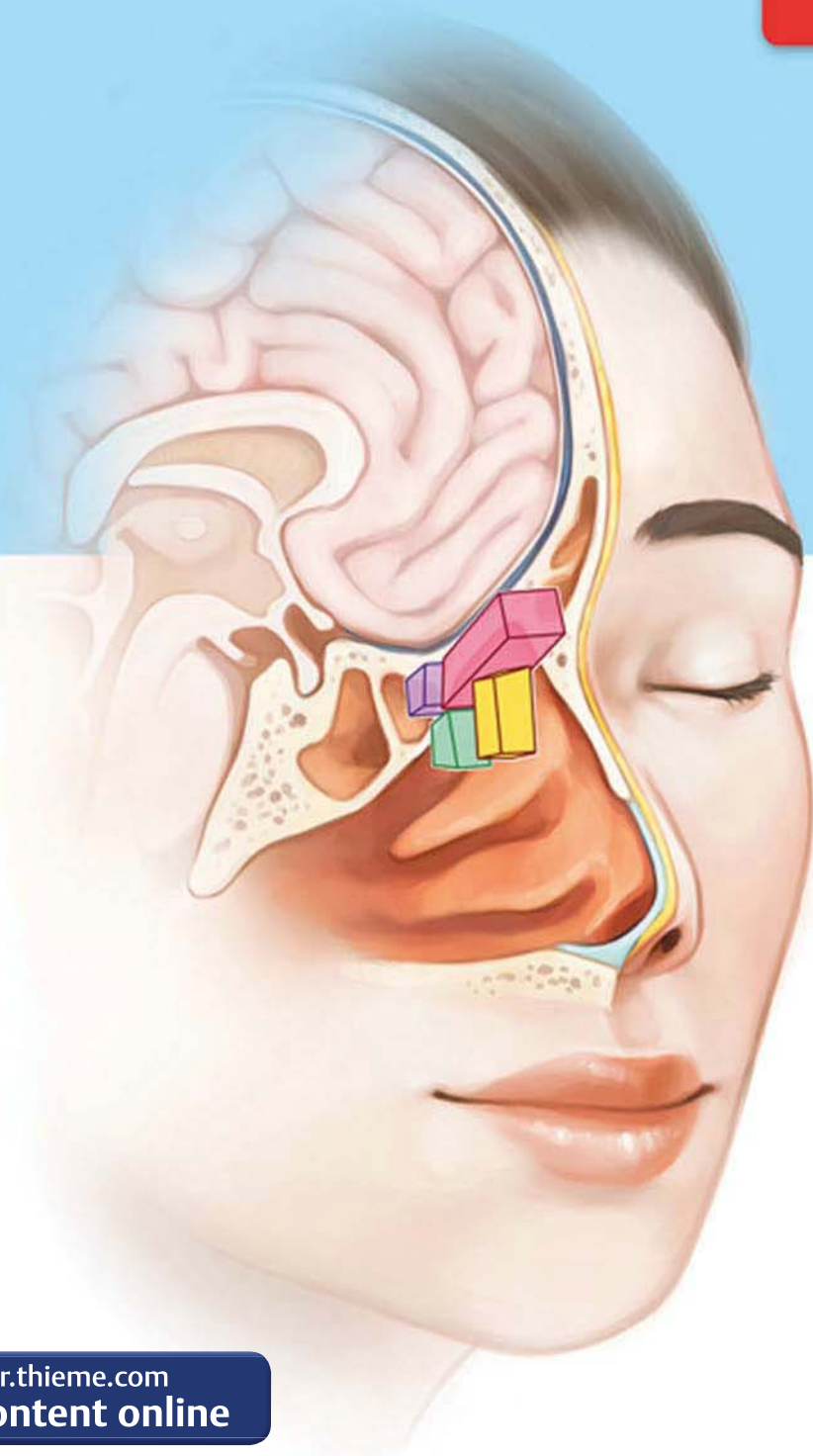
Endoscopic Sinus Surgery

Anatomy, Three-Dimensional Reconstruction,
and Surgical Technique

Peter-John Wormald

Fourth Edition

plus videos



 MediaCenter.thieme.com
plus e-content online

 Thieme

Endoscopic Sinus Surgery

Anatomy, Three-Dimensional Reconstruction,
and Surgical Technique

Fourth Edition



Endoscopic Sinus Surgery

Anatomy, Three-Dimensional Reconstruction, and Surgical Technique

Fourth Edition

Peter-John Wormald, MD, FRACS, FCS(SA), FRCS(Ed), MBChB
Chairman and Professor of Otolaryngology–Head and Neck Surgery
Professor of Skull Base Surgery
University of Adelaide
Adelaide, South Australia
Australia

Thieme

New York • Stuttgart • Delhi • Rio de Janeiro

Executive Editor: Timothy Hiscock
Managing Editor: J. Owen Zurhellen IV
Editorial Assistant: Mary B. Wilson
Director, Editorial Services: Mary Jo Casey
Production Editor: Heidi Grauel
Editorial Director: Sue Hodgson
International Production Director: Andreas Schabert
International Marketing Director: Fiona Henderson
International Sales Director: Louisa Turrell
Institutional Sales Director: Adam Bernacki
Senior Vice President and Chief Operating Officer: Sarah Vanderbilt
President: Brian D. Scanlan
Printer: Everbest Printing Co.

Library of Congress Cataloging-in-Publication Data

Names: Wormald, P. J., author.
Title: Endoscopic sinus surgery : anatomy, three-dimensional reconstruction, and surgical technique / Peter-John Wormald.
Description: Fourth edition. | New York : Thieme, [2018] | Includes bibliographical references and index.
Identifiers: LCCN 2017025854 | ISBN 9781626234697 | ISBN 9781626234703 (ebook)
Subjects: | MESH: Paranasal Sinuses—surgery | Paranasal Sinuses—anatomy & histology | Paranasal Sinus Diseases—surgery | Natural Orifice Endoscopic Surgery—methods | Video-Assisted Surgery
Classification: LCC RF421 | NLM WV 340 | DDC 617.5/23—dc23
LC record available at <https://lccn.loc.gov/2017025854>

Important note: Medicine is an ever-changing science undergoing continual development. Research and clinical experience are continually expanding our knowledge, in particular our knowledge of proper treatment and drug therapy. Insofar as this book mentions any dosage or application, readers may rest assured that the authors, editors, and publishers have made every effort to ensure that such references are in accordance with **the state of knowledge at the time of production of the book.**

Nevertheless, this does not involve, imply, or express any guarantee or responsibility on the part of the publishers in respect to any dosage instructions and forms of applications stated in the book. **Every user is requested to examine carefully** the manufacturers' leaflets accompanying each drug and to check, if necessary in consultation with a physician or specialist, whether the dosage schedules mentioned therein or the contraindications stated by the manufacturers differ from the statements made in the present book. Such examination is particularly important with drugs that are either rarely used or have been newly released on the market. Every dosage schedule or every form of application used is entirely at the user's own risk and responsibility. The authors and publishers request every user to report to the publishers any discrepancies or inaccuracies noticed. If errors in this work are found after publication, errata will be posted at www.thieme.com on the product description page.

Some of the product names, patents, and registered designs referred to in this book are in fact registered trademarks or proprietary names even though specific reference to this fact is not always made in the text. Therefore, the appearance of a name without designation as proprietary is not to be construed as a representation by the publisher that it is in the public domain.

Copyright © 2018 by Thieme Medical Publishers, Inc.

Thieme Publishers New York
333 Seventh Avenue, New York, NY 10001 USA
1-800-782-3488, customerservice@thieme.com

Thieme Publishers Stuttgart
Rüdigerstrasse 14, 70469 Stuttgart, Germany
+49 [0]711 8931 421, customerservice@thieme.de

Thieme Publishers Delhi
A-12, Second Floor, Sector-2, NOIDA-201301
Uttar Pradesh, India
+91 120 45 566 00, customerservice@thieme.in

Thieme Publishers Rio de Janeiro, Thieme Publicações Ltda.
Edifício Rodolpho de Paoli, 25º andar
Av. Nilo Peçanha, 50 – Sala 2508
Rio de Janeiro 20020-906 Brasil
+55 21 3172-2297 / +55 21 3172-1896

Printed in China by Everbest Printing Co. 5 4 3 2 1

ISBN 978-1-62623-469-7

Also available as an e-book:
eISBN 978-1-62623-470-3



This book, including all parts thereof, is legally protected by copyright. Any use, exploitation, or commercialization outside the narrow limits set by copyright legislation without the publisher's consent is illegal and liable to prosecution. This applies in particular to photostat reproduction, copying, mimeographing or duplication of any kind, translating, preparation of microfilms, and electronic data processing and storage.

Dedicated with love to Fiona, my wife, without whom this book would not have been possible, and to Nicholas and Sarah, my children who provide my inspiration.

Preface

This fourth edition of *Endoscopic Sinus Surgery* and its accompanying videos continue to refine and improve the concepts and illustrations of the third edition. With time, surgical techniques are refined and adjusted and these have been added to this edition. Each chapter has been thoroughly revised and although some have required minimal changes, others have undergone extensive revision and adjustment. A recent publication (Wormald PJ, et al. The International Frontal Sinus Anatomy Classification [IFAC] and Classification of the Extent of Endoscopic Frontal Sinus Surgery [EFSS]. *Int Forum Allergy Rhinol* 2016;6[7]:677–696) simplifying the terminology of the cells in the frontal recess (IFAC classification) has resulted in extensive revision of the frontal sinus chapters. This new classification of cells in the frontal recess is both simple and logical and we hope will be adopted as the new world standard for naming of these cells. In addition, there has long been a need for a new classification of the extent of surgery. There has been much confusion about previous classifications with different interpretations for the extent of surgery. The classification of the extent of frontal sinus surgery (EFSS) was also revised in the same publication and again is simple and logical and we hope will become accepted as the world standard for the grading for the extent of surgery. We acknowledge Rowan Valentine's contribution to this book with the high standard of dissection images he has provided. These images were obtained under the guidance of the late Albert L. Rhoton Jr. in the latter's laboratory in Gainesville, Florida. The images in this book reflect the high

standard of excellence associated with Rowan's work. In this new edition, we continue to develop and refine surgical techniques. We have added the mega-antrostomy and prelacri-mal approaches to the maxillary sinus and adjusted the use of anterior based pedicled flaps for the EFSS grade 6 (frontal drillout) procedure and refined many of the other surgical techniques presented.

This book differs from many others on anatomy and surgical techniques in that its scope is purely anatomical and operative. No attempt is made to cover the pathology or medical treatment of any of the conditions discussed—such information can be found in several excellent texts currently available. Many of the operative techniques presented in this book are novel but the results achieved with them have been carefully audited and published in peer-reviewed journals before they are presented here. It is hoped that the description of the relevant anatomy and surgical techniques in this text are sufficiently clear so that the reader will be able to apply them in his/her everyday practice. The concepts are presented with extensive use of illustrations, CT and MRI scans, and intraoperative and postoperative photographs. In addition, the accompanying videos illustrate the surgical techniques described in the text. This combination of text and videos should reinforce understanding of sinus anatomy and give the surgeon the confidence to tackle the many anatomical variations and technical challenges that may occur during endoscopic sinus and skull base surgery.

Acknowledgments

A book of this nature is an accumulation of all knowledge gleaned from many teachers over many years. However, I would like to single out the late Mike McDonogh as the teacher who had the greatest influence on my career as a rhinologist. Mike was an exceptional person who was highly innovative, and his humor, wit, and intelligence will be greatly missed. His ideas led to the development of the swing-door uncinectomy and the bath-plug closure of cerebrospinal

leaks. I will remain forever indebted to him for his teaching, mentoring, and friendship.

Andrew van Hasselt deserves a special mention for his support over many years. In addition, I would like to thank the Australian ENT Society members for making me welcome in Australia and for their ongoing support of the development of academic ENT.

1 Setup and Ergonomics of Endoscopic Sinus Surgery

◆ Introduction

There has been a significant shift from external and head-light sinus surgery to endoscopic sinus surgery (ESS). This dramatic change was initiated by the pioneering studies of Messerklinger in which he demonstrated that each sinus has a predetermined mucociliary clearance pattern draining toward its natural ostium irrespective of additional openings that may have been created into the sinuses.¹ This philosophy of opening the natural ostium of the diseased sinus was then popularized by Stammberger² and Kennedy.³ ESS is now accepted as the surgical management of choice for chronic sinusitis. In addition, as our knowledge of the anatomy of the sinuses has improved, other ancillary techniques such as endoscopic lacrimal surgery⁴ and orbital decompression⁵ have been developed. The development of specialized instruments has facilitated the endoscopic management of benign endonasal tumors^{6,7} and more recently the endoscopic management of malignant tumors⁸ of the nose, sinuses, and intracranial cavity. Endoscopic sinus surgery, ancillary nasal and sinus procedures, and, more recently, endoscopic transnasal intracranial surgery requires a broad range of specially designed endoscopic surgical instruments.

◆ Instruments

Disclaimer

A number of instruments that are presented in this book are manufactured and sold by Medtronic ENT and Integra. Those that are identified by an * have been designed by the author and a royalty is received from the sale of these instruments. There are no undeclared financial incentives associated with any of the instruments discussed that do not bear the identifying *.

A complete list of endoscopic sinus surgery instruments used by the author is presented in **Table 1.1**. If the instrument is produced by a number of companies, no manufacturer is named. If a particular instrument is produced by only one company, then the manufacturer is named. The following instruments are important for basic sinus surgery:

- ◆ Small rotating backbiting forceps
- ◆ Sickle knife
- ◆ Small (2.5-mm) straight and 45-degree upturned Blakesley forceps
- ◆ Small (2.5-mm) straight and 45-degree upturned through-biting (cutting) Blakesley forceps
- ◆ Endoscopic scissors
- ◆ Double right-angled ball probe
- ◆ Forceps 45- and 90-degree giraffe cup, 45- and 90-degree through-biting giraffe forceps
- ◆ Hajek Koeffler forward-biting punch
- ◆ Suction Freer's elevator
- ◆ Curettes (straight, 45-degree, and 90-degree curette)
- ◆ Malleable suction Freer's elevator* (Integra, Plainsboro, NJ)
- ◆ Malleable suction curette* (Integra)
- ◆ Malleable frontal sinus probe* (Integra)

Powered Microdebriders

Powered microdebriders now form an essential part of the instrumentation required to perform ESS and skull base surgery. These instruments allow the surgeon to remove blood from the operating field with the gate open and then with considerable precision the tissue can be cut by the rotating inner blade of the microdebrider. This precision cutting of mucosa minimizes the potential for stripping of the mucosa and helps to achieve maximum mucosal preservation which should improve postoperative healing and consequently the results of the surgery. These instruments are very effective at removing tissue and if placed in the wrong area, such as the orbit, can create significant damage to the orbital contents in a

Table 1.1 Full list of operating instruments and equipment

<p>Instruments</p> <p>Jacobson angled 7-inch needle holder 6-inch fine needle holder Small Luc forceps Angled Heyman turbinectomy scissors Tilley Henkel forceps Tilley packing forceps Mosquito curved artery clips Backhaus towel clips Sponge holder McIndoe forceps Adson toothed OR Adson Brown forceps Adson plain OR tungsten tip forceps Suture scissors Iris curved scissors No. 7 scalpel blade handle Freer's dissector Frazier 9 French gauge sucker and stilette Frazier 10 French gauge sucker and stilette Dental syringe Heath's mallet Small Killian's speculum Medium Killian's speculum Large Killian's speculum</p> <p>Sinoscopy instruments</p> <p>Medium straight Blakesley forceps Medium upturned Blakesley forceps Blakesley forceps straight through cut Blakesley forceps upturned through cut Right ostrum punch downcut Left ostrum punch downcut Sinus short sucker Sinus long sucker Sickle knife Freer's dissector Double-ended probe Kuhn Bolger frontal ostium seeker Kuhn Bolger frontal sinus curette 55 degrees Antrum curette 90-degree curette Sucker Freer's and stiletto Rotating microbite backbiter Hajek Koffler sphenoid punch upcut forward</p> <p>Special instruments</p> <p>Sinoscopy scissors – straight Sinoscopy scissors – curved left Sinoscopy scissors – curved right Kuhn Bolger giraffe forceps horizontal Kuhn Bolger giraffe forceps vertical Kuhn Bolger forceps 60 degrees Kuhn Bolger forceps 90 degrees Kuhn Bolger forceps 90 degrees right angled Kuhn Bolger forceps 90 degrees left angled Ligature clip carrier</p> <p>Wormald Sucker Bipolar* Integra</p> <p>Wormald's suction bipolar forceps – straight* Wormald's suction bipolar forceps – upturned* Sterilization case Bipolar cable</p> <p>Medtronic ENT frontal trephine set</p> <p>Medtronic frontal trephine set Drill guide</p>	<p>Drill pin Irrigation cannula (reusable; keep six in stock) Sterilizing tray</p> <p>Wormald's Malleable Frontal Sinus Instruments* Integra</p> <p>Wormald malleable frontal sinus probe Wormald malleable frontal sinus suction Wormald malleable elevator blunt Wormald malleable frontal sinus curette Sterilization tray</p> <p>Wormald Dacryocystorhinostomy Set* Integra</p> <p>Sickle knife Spear knife Lusk microbite forceps</p> <p>Wormald MicroFrance Anterior Skull Base and Pituitary Instrument Set* Integra</p> <p>5-mm fine scissors: left, right, and straight 5-mm fine scissors: up 8-mm fine scissors: left, right, and straight 8-mm fine scissors: up 1-mm forceps straight and 45 degrees Malleable probe straight Malleable probe right-angled hook Malleable suction dissector Malleable suction Malleable suction cage Malleable small and large 45-degree ring curettes Malleable small and large 90-degree ring curettes Bending tool</p> <p>MicroFrance Medtronic Hemorrhage Control Set* Integra</p> <p>Clamp straight rotatable Clamp curved small Clamp curved long Clamp 45-degree straight Clamp 45-degree curved small Clamp 45-degree curved long Clip-applying forceps rotatable straight Clip-applying forceps rotatable 45 degrees Needle holder rotatable</p> <p>Equipment</p> <p>Camera system</p> <p>STORZ HD digital camera SPIES 0-degree endoscope (4 × 11 mm Hopkins) 30-degree endoscope 45-degree endoscope 70-degree endoscope</p> <p>Lens washer</p> <p>Medtronic Endoscrub II</p> <p>Consumables</p> <p>0-degree Endoscrub II sheath 30-degree Endoscrub sheath</p> <p>Microdebrider</p> <p>Medtronic IPC (integrated power console) M5 handpiece Midas Rex Stylus handpiece Skull base burs</p> <p>Solutions</p> <p>Topical</p> <p>Cocaine solution (10% – 2 mL) Adrenaline (1:1000 × 1 mL) Normal saline (0.9 × 3 mL)</p>
---	--

*Instruments identified by an asterisk were designed by the author.

very short space of time.^{9,10} Due to its soft consistency, orbital fat can be sucked into the blade opening and cut by the rotating inner blade at a frightening rate. If the surgeon is unaware of having penetrated the orbital periosteum with microdebrider, significant damage can occur within a few seconds. There are numerous case reports in the literature in which powered microdebriders have caused inadvertent injury to the orbital contents and to the medial rectus muscle.^{9,10}

The blade is used in oscillate mode for the majority of the surgery. Most of the instruments have a default setting that will allow the blade to oscillate at 3000 or 5000 revolutions per minute. The foot pedal will also usually have a switch to allow the surgeon to select either variable or full speed when the pedal is depressed. Variable mode allows the surgeon to slow the speed whereas full speed will result in the blade turning at 3000 or 5000 rpm immediately as the pedal is depressed. It is important to understand that the speed at which the blade turns determines the amount of tissue that is cut. The higher the speed the less time the port is open and the less tissue is able to be sucked into the blade before the turning blade cuts the tissue. Conversely, the slower the speed the more tissue is sucked in and the more aggressively the blade cuts. **Fig. 1.1a** shows the blade in open mode and **Fig. 1.1b** shows tissue being sucked into the port of the blade before rotation of the blade cuts the tissue.

In forward and reverse mode the revolutions may vary from 3000 to 12,000 rpm and consequently the blade is open for only a very short period of time. Tissue cutting in this mode is thus severely limited. Forward mode is usually used for the various bur attachments that can be used in place of the blade. However, forward mode can also be used for very gently shaving bony septations on the lamina papyracea or skull base. This needs to be done with absolute knowledge of the anatomy and great care as inadvertent penetration of either structure can be disastrous. When this is done, the septations are brushed with the rotating blade without any use of pressure.

Endoscopic High-Speed Drills

Medtronic ENT (Minneapolis, MN) has a microdebrider base box that takes both a microdebrider handpiece with power range up to 30,000 rpm and all standard microdebrider blades and burs. The new burs designed to be run at 30,000 rpm come in a variety of angles as well as cutting or diamond options. This high-speed bur is very efficient at

removing large amounts of bone quickly and has resulted in much shorter operating times for procedures requiring bone removal. A caution must be added that the efficiency of these burs and the high speed at which they function may contribute added risk to the surgery as quick bone removal may result in breach of the skull base and intracranial penetration or orbital penetration. Experience and care is required when using the high-speed burs. In addition, this base box also takes an electronic endoscopic high-speed drill (Stylus) with curved irrigated diamond and cutting burs with power range up to 60,000 rpm. The surgeon can switch between the standard hand piece with drill (M5) and the high-speed electric drill by simply touching the button on the foot pedal. This high-speed electric drill, although irrigated, does not have in-built suction like a normal microdebrider drill and therefore is more suitable in a two-surgeon setup where the second surgeon can provide suction during drilling.

Endoscope Cleaners

A large number of companies manufacture endoscope cleaners or scrubbers. These are designed to wash the lens of the endoscope should it become obscured with blood. If the surgical field is bloody, the endoscope cleaner keeps the scope lens clear of blood and allows the operation to proceed without the need to remove the endoscope from the nose and manually clean it. The endoscope cleaner speeds up the operation and improves the safety of the surgery by maintaining visibility and decreasing the surgeon's frustration level by allowing the surgery to progress more rapidly.

Cameras and Monitors

Surgery was originally performed by the surgeon looking through the eye piece of the endoscope but this traditional technique is seldom used anymore. Currently, most surgeons connect a video camera to the endoscope which enables the surgeon to operate using the view on the monitor. A significant advantage of operating from the monitor is the ergonomic advantage this affords the surgeon as he or she can sit or stand next to the patient and not have to bend either their back or neck to obtain a view of the nasal cavity. This is especially valuable if the frontal recess is being operated upon as the surgeon viewing the procedure through the eyepiece

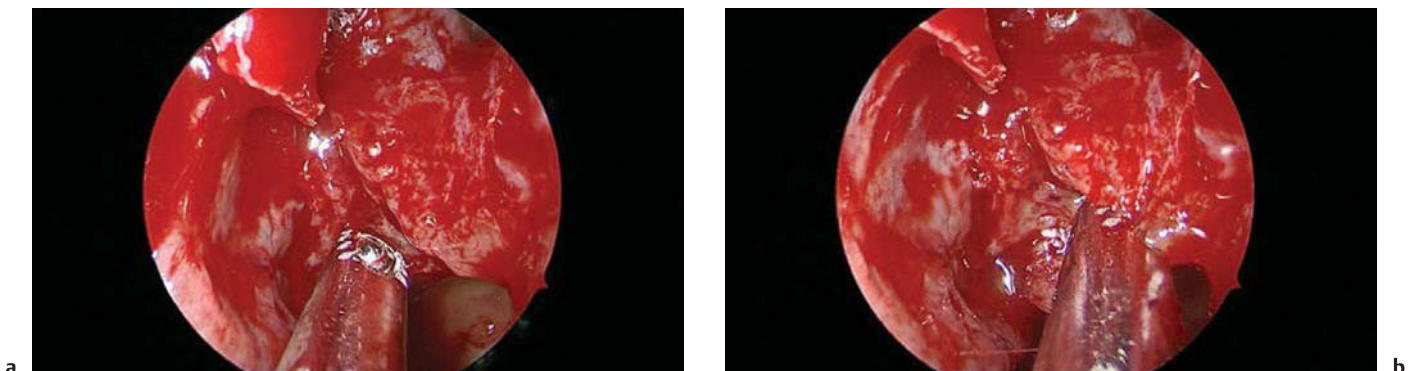


Fig. 1.1 (a) The blade open and (b) with tissue being sucked into the blade prior to rotation of the inner blade and severing of the tissue.

may have to almost have their head on the patient's chest to obtain an adequate view. In addition, if a large instrument such as the microdebrider is been used at the same time, this instrument may touch the surgeon's head when it is being manipulated into tight spaces. The monitor provides a large magnified image that can be advantageous for delicate work (e.g., optic nerve, skull base, and intracranial surgery) and it allows two surgeons to operate together (pituitary, infratemporal fossa, and intracranial surgery). Another major advantage of operating from the monitor is that it allows a senior surgeon to monitor the trainee's surgery and allows the trainee (and all in the operating room) to watch the senior surgeon operate. The nurse can anticipate the surgical instrument required for the next step and the anesthetist can monitor the operating field and undertake anesthetic interventions to improve the surgical field as required. If the surgeon is operating from the monitor, a high definition digital camera is required with a powerful light source and medical grade monitor. Analog cameras generally do not cope well with blood in the surgical field and depth perception and tissue contrasts can be lost. If inferior cameras are used, visibility and orientation become increasingly difficult for the surgeon and the risk of complications increases.

◆ Position of the Patient and the Surgeon

My preference is to sit at the right-hand side of the patient. The surgeon may stand but if his or her elbow is not resting on the operating table, the monitor image tends to move excessively, reflecting the instability of the hand holding the endoscope. The patient should be supine and the operating table tilted a minimum of 15 degrees up to 30 degrees anti-Trendelenburg. The patient's head should be in a neutral position (neither flexed nor extended). This allows the surgeon to operate in a plane parallel to the skull base, which diminishes the risk for skull base injury by decreasing the

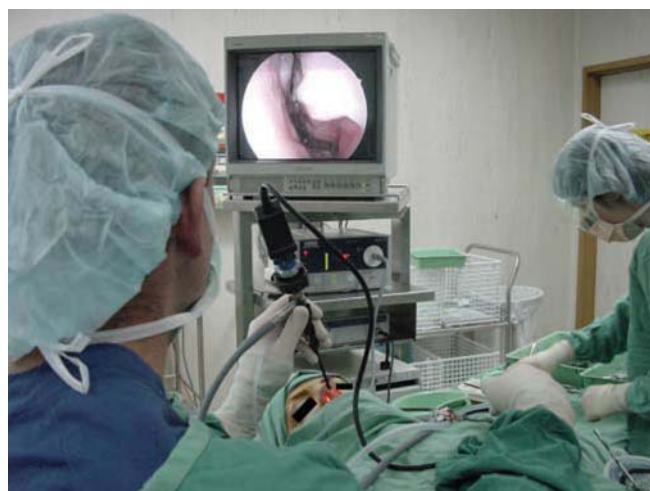

Fig. 1.2 Picture of the operating setup with the surgeon, the patient's head, and the video monitor all in a straight line. The scrub nurse stands opposite the surgeon which allows a view of the monitor and facilitates the handing of instruments to the surgeon.

angle of approach. The video monitor should be positioned so that the surgeon, the patient's head, and the monitor are in a straight line (**Fig. 1.2**).

A thin arm board is placed next to the patient's head to widen the upper part of the operating table so that the surgeon can comfortably rest their elbow on the arm board. If this position is too low and extra height is needed, sterile drapes folded into a square are placed on the arm board to build this up. The patient's head can also be turned toward the surgeon which decreases the height at which the elbow needs to be supported. The scrub nurse should position his or her instrument table so that the far edge of the table is parallel with the head of the operating table. This allows the monitor stack to be placed in a straight line with the patient's head and surgeon (**Fig. 1.3**).

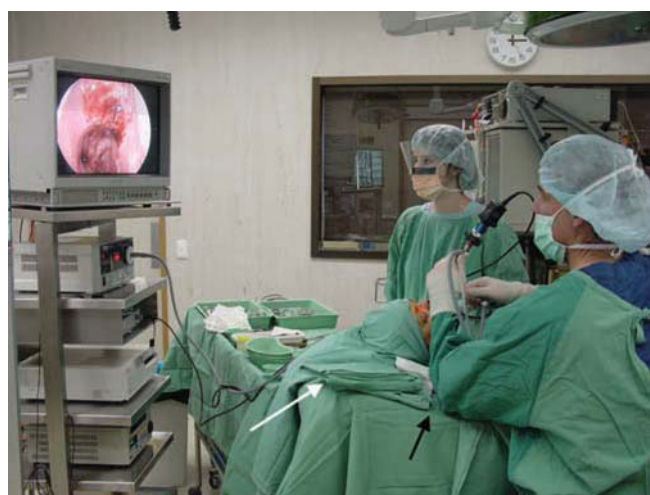
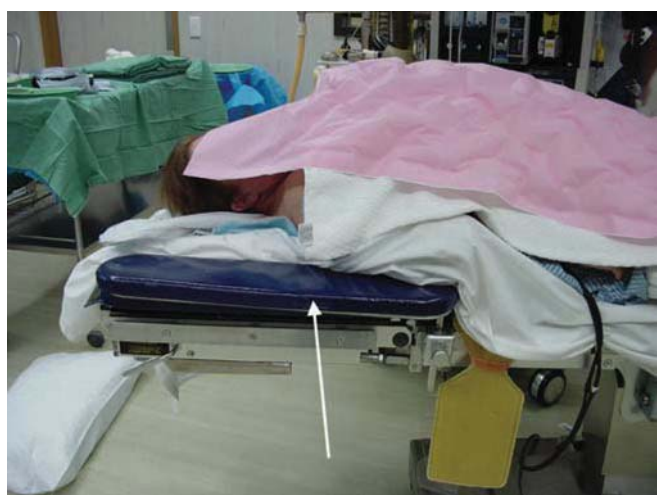
Fig. 1.3 The arm board is placed on the operating table (**a**) (*white arrow*) to allow the surgeon to rest their elbow (**b**) (*black arrow*) to stabilize the camera. This allows the surgeon's forearm and wrist to be straight which is ergonomically comfortable for the surgeon. It also ensures that the monitor picture is stable (**b**). The height of the elbow can be adjusted with sterile towels (*white arrow*) as required.

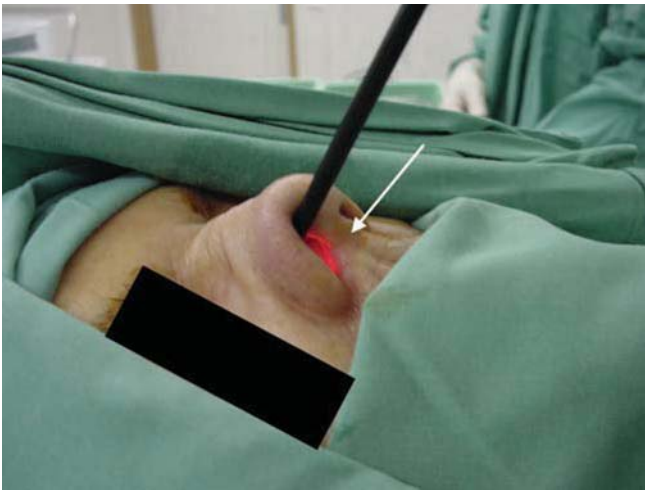


Fig. 1.4 The scope is used to tent the nasal vestibule superiorly creating space below the endoscope (*white arrow*) through which the instrument is passed into the nose.

◆ Principles of Endoscope Placement and Instrument Placement during ESS

With the surgeon's elbow resting on the added arm board, the endoscope is slid into the nose. The endoscope should then be pushed as far superiorly as possible. This should distort the nasal vestibule by placing the endoscope high in the nasal vestibule. This creates a space in the nasal vestibule below the endoscope through which all instruments are placed (**Fig. 1.4**).

The endoscope and the instruments should never cross during surgery. It is only very rarely when dissecting in the frontal sinus with a 70-degree endoscope that the endoscope needs to be placed below the instrument. When this is done, the surgeon loses sight of the tip of the instrument and accurate and careful dissection is no longer possible. The 0-degree endoscope should be used whenever possible

and in the techniques described in the following chapters it is used unless otherwise stated. This makes the surgery as simple as possible and decreases the risk of unnecessary injury to the adjacent or surrounding mucosa during passage of the endoscope and instrument. It also limits the risk of disorientation that can occur when using angled endoscopes. If angled endoscopes are used, instruments need to be curved so that the tip of the instrument can be manipulated in the center of the endoscope view (see Chapter 7). The greater the angle of the endoscope, the longer the curve needs to be on the instrument. The greater the angle of the endoscope and curve of the instrument, the greater the degree of difficulty of dissection so it is best to use the angled endoscopes (especially the 70-degree endoscope) as infrequently as possible during surgery.

References

1. Messerklinger W. Endoscopy of the nose. Munich: Urban and Schwarzenberg; 1978:52–54
2. Stammberger H. Endoscopic endonasal surgery—concepts in treatment of recurring rhinosinusitis. Part I. Anatomic and pathophysiologic considerations. *Otolaryngol Head Neck Surg* 1986;94(2):143–147
3. Kennedy DW. Functional endoscopic sinus surgery. Technique. *Arch Otolaryngol* 1985;111(10):643–649
4. Wee DTH, Carney AS, Thorpe M, Wormald PJ. Endoscopic orbital decompression for Graves' ophthalmopathy. *J Laryngol Otol* 2002;116(1):6–9
5. Wormald PJ. Powered endoscopic dacryocystorhinostomy. *Laryngoscope* 2001;112:69–72
6. Wormald PJ, Ooi E, van Hasselt CA, Nair S. Endoscopic removal of sinonasal inverted papilloma including endoscopic medial maxillectomy. *Laryngoscope* 2003;113(5):867–873
7. Wormald PJ, Van Hasselt A. Endoscopic removal of juvenile angiofibromas. *Otolaryngol Head Neck Surg* 2003;129(6):684–691
8. Knegt PP, Ah-See KW, vd Velden LA, Kerrebijn J. Adenocarcinoma of the ethmoidal sinus complex: surgical debulking and topical fluorouracil may be the optimal treatment. *Arch Otolaryngol Head Neck Surg* 2001;127(2):141–146
9. Graham SM, Nerad JA. Orbital complications in endoscopic sinus surgery using powered instrumentation. *Laryngoscope* 2003;113(5):874–878
10. Bhatti MT, Giannoni CM, Raynor E, Monshizadeh R, Levine LM. Ocular motility complications after endoscopic sinus surgery with powered cutting instruments. *Otolaryngol Head Neck Surg* 2001;125(5):501–509

2 The Surgical Field in Endoscopic Sinus Surgery

◆ Introduction

The presence of significant bleeding in the surgical field is a critical factor in the potential success or failure of endoscopic sinus surgery (ESS).¹⁻⁴ When significant bleeding is present, recognition of anatomical landmarks becomes difficult.²⁻⁴ Bleeding obscures surgical planes and makes the identification of the drainage pathways of the sinuses difficult. Cell walls become difficult to distinguish from the lamina papyracea or skull base and the risk of causing complications increases.^{3,4} If the patient has significant inflammation of the sinuses, from chronic infection or the presence of pus/fungal debris, increased vascularity will often contribute to more bleeding.^{2,5} If the surgeon attempts to manipulate an instrument in the surgical field after the discernable anatomy is covered in blood, the risk of a complication increases. In addition, greater surgical trauma may occur, cells may be left behind, and there is an increased likelihood of postoperative scarring and failure of the surgical procedure. It is therefore critical to optimize the surgical field and in so doing make the surgical dissection as easy as is possible.²⁻⁴

Our department has a special interest in this aspect of ESS and has conducted a number of double-blind randomized controlled studies in an attempt to establish which maneuvers to reduce bleeding are worthwhile. To date, not all maneuvers have been scientifically evaluated but where there is evidence for a specific maneuver this is presented. The first important issue to address is a grading system for bleeding in the surgical field. Boezaart and van der Merwe described and validated a grading system of five grades presented in **Table 2.1**.³

Although this grading system is valuable, we have found that the majority of surgical fields are around grade 3 with some grade 2 and some grade 4.² Only on rare occasions are grade 1 and 5 fields encountered. This tends to compress the grading system and makes differentiation of more subtle changes difficult. Grade 3 may need to be further divided to allow variation within grade 3 to be discerned.² We have recently developed and validated an endoscopic sinus surgical

field score, which separates the middle grades and allows more accurate grading of the surgical field (**Table 2.2**).

◆ Local versus General Anesthetic

Local anesthetic has the advantage of not inducing generalized vasodilatation. Increased circulating catecholamines may also improve the surgical field by continuing to act on the prearteriolar and precapillary sphincters. However, there are a number of limitations to local anesthetics:

- ◆ Patient anxiety and sudden patient movement during delicate surgery can be problematic
- ◆ Surgery takes between 1 and 2 hours. Some patients (especially older patients) have difficulty remaining still for this length of time
- ◆ Appropriate anesthesia needs to be achieved in all the sinuses and the nasal cavity,
- ◆ If the procedure is bloody the patient may have difficulty dealing with the volume of blood trickling into the pharynx. If the patient is sedated aspiration can occur.
- ◆ Water from the scope scrubber may add to the secretions in the pharynx that the patient needs to deal with
- ◆ Teaching of residents can be more difficult when the patient is awake

In our department, local anesthetic is offered to patients having limited ESS confined to the middle meatus. We prefer general anesthesia for ESS that involves the frontal recess and/or posterior ethmoids and/or sphenoids.

◆ Standard Nasal Preparation for ESS

Laryngeal Mask versus Endotracheal Intubation

It is our current practice to use laryngeal masks rather than endotracheal intubation for all our patients undergoing

Table 2.1 Boezaart and van der Merwe grading system for bleeding during endoscopic sinus surgery³

Grades	Surgical field
Grade 1	Cadaveric conditions with minimal suction required
Grade 2	Minimal bleeding with infrequent suction required
Grade 3	Brisk bleeding with frequent suction required
Grade 4	Bleeding covers surgical field after removal of suction before surgical instrument can perform maneuver
Grade 5	Uncontrolled bleeding; bleeding out of nostril on removal of suction

sinus surgery. The rationale for this is that it allows the patient to be kept under a lighter general anesthetic with less vasodilatation and less intraoperative bleeding. In addition, the patient does not cough and strain on the endotracheal tube as they recover from the anesthetic, avoiding the venous congestion and subsequent hemorrhage often associated with such straining. One of the potential downsides of a laryngeal mask is the possibility of contamination of the upper airway by blood. This is prevented by the placement of a small throat pack above the laryngeal mask in the back of the throat to catch any blood from the nasal cavity. Another possible downside is the potential difficulty with ventilation of the patient during surgery. Our standard protocol is total intravenous anesthesia (TIVA) with a laryngeal mask in a nonparalyzed patient. The remifentanyl infusion (part of TIVA) suppresses spontaneous ventilation and allows the patients to be ventilated through the laryngeal mask. The lack of paralysis provides additional safety against intraoperative awareness because the patient should move if the level of anesthesia becomes too light.

Table 2.2 The Wormald grading system for bleeding during endoscopic sinus surgery

Grade	Surgical Field
0	No bleeding
1	1–2 points of ooze (no blood in the sphenoid)
2	3–4 points of ooze (no blood in the sphenoid)
3	5–6 points of ooze (slight blood accumulation in the sphenoid)
4	7–8 points of ooze (moderate blood accumulation of sphenoid—fills after 90 seconds)
5	9–10 points of ooze (sphenoid fills after 60 seconds)
6	> 10 points of ooze, obscuring surface (sphenoid fills between 40 and 60 seconds)
7	Mild bleeding/oozing from entire surgical surface with slow accumulation of blood in post nasal space (sphenoid fills by 40 seconds)
8	Moderate bleeding from entire surgical surface with moderate accumulation of blood in post nasal space (sphenoid fills by 30 seconds)
9	Moderately severe bleeding with rapid accumulation of blood in post nasal space (sphenoid fills by 20 seconds)
10	Severe bleeding with nasal cavity filling rapidly (sphenoid fills in < 10 seconds)

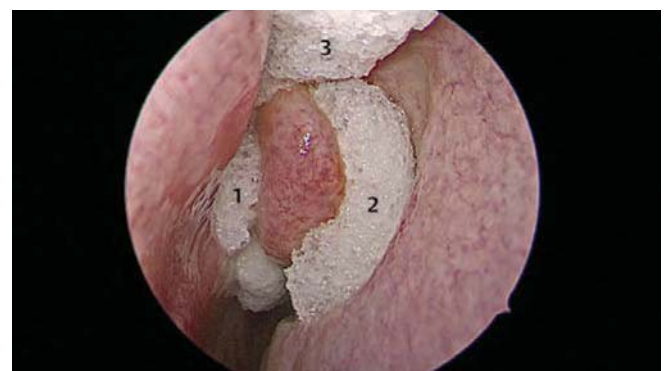Positioning the Patient

The positioning of the patient is described in Chapter 1. It is important to have the patient 30-degrees head up so that the venous return from the head and neck is facilitated. This puts the patient's head above the chest, which lowers the arterial pressure and prevents venous congestion, and thereby improves the surgical field.⁶

Topical Vasoconstriction

In a study recently published, we showed that any packing material placed in the nasal cavity tends to cause damage to the nasal mucosa.⁷ The more abrasive the packing, the worse the trauma.⁶ Taking this into consideration, the least abrasive packing material is used, namely the neurosurgical Cottonoid patties (Codman, Boston, MA) or a standard Merocel (Medtronic ENT, Minneapolis, MN) nasal pack cut into six pieces. The anesthetist is consulted to ensure there is no contraindication to the use of cocaine. If there is a concern, then 1% oxymetazoline is used in place of cocaine. In an adult patient, a mixture of 2 mL of 10% cocaine, 1 mL of 1:1000 adrenaline, and 4 mL of saline is divided into two portions, with half used to soak six neuropatties or Merocel pieces. These six pieces are placed in the nose once the patient is anesthetized. The other half of the cocaine mixture and, if a standard 10 neuropattie pack was used, the remaining four neuropatties are kept sterile on the instrument trolley for later use during surgery if required. Three Cottonoids/pieces are placed on each side directly after intubation using a Freer's elevator to manipulate them gently into place. The first is placed in the sphenothmoidal recess, the second under the middle turbinate, with the third being placed over the axilla of the middle turbinate (**Fig. 2.1**). If there is a concha bullosa or significantly lateralized middle turbinate, the Cottonoid is placed along the inferior margin of the middle turbinate. No force is used to position the Cottonoid in the middle meatus.

As only half the solution is used at the beginning of surgery, the total dose of cocaine that the patient is exposed to is about 100 mg. The toxic dose of cocaine is 3 mg/kg without

**Fig. 2.1** Placement of the Merocel pieces in the left nasal cavity prior to surgery. A Merocel piece is in the sphenothmoidal recess (1), another is in the middle meatus (2), and another is in the region of the axillary flap (3).

the simultaneous use of adrenaline. It has also been shown that the presence of adrenaline inhibits mucosal absorption and that a proportion of the solution will remain in the pack. This decreases the amount of cocaine that the patient is exposed to and the doses used are well below the toxic dose in adult patients. The dose needs to be appropriately adjusted in children.

Local Infiltration

A 2% solution of lidocaine (lignocaine in the UK and Australia) with either 1:80,000 or 1:100,000 adrenaline is administered with a dental syringe and needle. The injections are given after the patient has been draped and the camera and endoscope are available. Under endoscopic guidance, the area above the middle turbinate is infiltrated. This is followed by infiltration into the anterior end of the middle turbinate. Note that the area anterior to the uncinate is not infiltrated as bleeding from an injection site can obscure the uncinate during its removal. In some patients, where there is an expected increased likelihood of bleeding, a third injection is given into the back end of the middle turbinate in the region of the sphenopalatine artery. A spinal needle is used as the dental needle is usually not long enough to reach this area. **Fig. 2.2** illustrates the routine infiltration points used.

Preoperative Antibiotics and Steroids

Inflammation increases the vascularity of tissues and when surgery is conducted on highly inflamed tissues, increased bleeding results. Patients with acute sinusitis, who have an infective complication requiring surgery, will often have a very bloody surgical field. It therefore stands to reason that

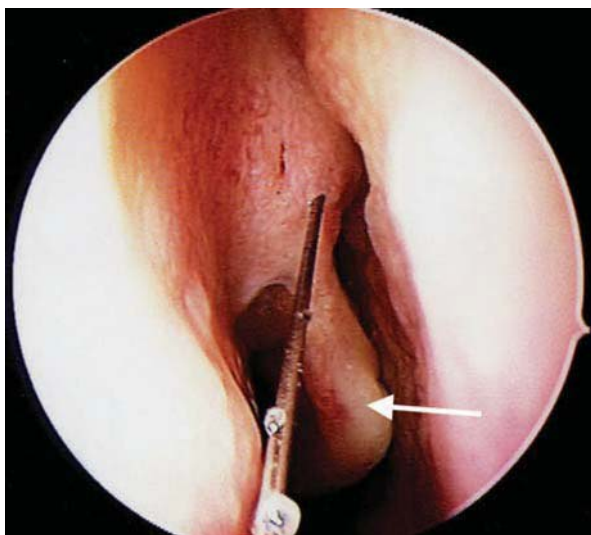

Fig. 2.2 Injection sites in the right nasal cavity for local anesthetic prior to endoscopic sinus surgery. The needle is in the region of the axillary flap and the *white arrow* indicates the injection site on the anterior end of the middle turbinate.

using antibiotics in patients with a significant infection preoperatively should improve the surgical field. However, most of our patients undergoing ESS have had extended medical therapy which normally includes numerous courses of antibiotics and often systemic steroids, and therefore rarely have an acute infection present. The value of using antibiotics preoperatively in this elective patient group is unknown as there are no well-designed studies addressing this issue. The important questions that remain unanswered are the type of antibiotic, the length of time it should be used before surgery, and the patient group most likely to benefit from preoperative use. Currently, I do not routinely place patients on antibiotics preoperatively.

It has been suggested that patients with significant nasal polyposis may benefit from a course of preoperative steroids.⁸ The theory is that steroids should decrease the size of the polyps and the vascularity associated with these polyps. A recently published study evaluated the effect of preoperative steroids on the degree of bleeding during sinus surgery.⁸ In this study prednisone, 30 mg daily was given for 5 days preoperatively and the results showed a significant improvement in a visual analog grading of the surgical field during surgery.⁸ However, it remains unclear what doses of steroids should be given, for how long, and to which patient groups. Empiric treatment regimens range from 30 mg⁸ to 50 mg of prednisone daily for between 3 and 7 days preoperatively, and is usually only utilized in nasal polyposis patients.

The Blood Pressure during ESS

One of the critical factors that the anesthetist can control during surgery is the blood pressure. This is usually presented as the mean arterial pressure (MAP) and calculated by $MAP = \text{diastolic pressure} + 1/3(\text{systolic pressure} - \text{diastolic pressure})$. Hypotensive anesthesia (defined as a MAP of 50–70 mm Hg) is a well described technique and frequently used in cardiac, orthopaedic, and spine surgery.^{9,10} Its use in ESS procedures has also been described⁹ but its value has been controversial with risk often considered to outweigh benefit.^{9,10} Although a recent article showed benefit of hypotensive anesthesia in ESS, it was still unclear as to what the optimal MAP is during ESS and if such a MAP is safe with regard to the perfusion of vital organs during the procedure. In our department, we designed a study to firstly assess if hypotensive anesthesia benefits the surgical field during ESS¹¹ and secondly at what MAP levels this is best achieved and, by using middle cerebral artery perfusion to assess organ perfusion, what MAP levels can be used with relative safety.¹² In the first study, although there was a clear statistical improvement in surgical fields with lower MAPs, most of the readings tended to be at lower MAPs which skewed the data as there were few MAPs at the higher end to show that the bleeding did get worse at higher MAPs.¹¹ The second study was designed so that the MAP was artificially elevated during surgery on one side then lowered into the hypotensive range for the second side.¹² Sides were randomized and the observers blinded to the MAP manipulations. In addition, in this study the cerebral perfusion as measured by an extracranial Doppler placed over the middle cerebral artery was measured

during the changes in blood pressure. These studies have conclusively shown that the most significant manipulation affecting the surgical field is the blood pressure and that the anesthetist should aim in a healthy patient without comorbidities for a MAP of around 65 mm Hg. Cerebral blood flow was minimally affected at a MAP of above 60 mm Hg and was considered safe. Although there were further improvements in the surgical field at MAPs of below 60 mm Hg, these were small and did not warrant the risk associated with the potential hypoperfusion of vital organs. Therefore, our current protocol is to ask the anesthetist to keep the MAP around 65 mm Hg. The methodology by which this is achieved is also important and detailed here.

Total Intravenous Anesthesia and Inhalational Agents

Inhalational agents used during general anesthesia cause peripheral vasodilatation by relaxing of the prearteriolar muscle sphincters.⁶ This significant peripheral vasodilatation usually results in mild hypotension.^{3,4,6} Peripheral vasodilatation with paralysis of the arteriolar and precapillary sphincters may result in significant bleeding if surgery is performed when the tissues of the nose and sinuses are inflamed.^{3,4,6} Any maneuver that attempts to lower the MAP using vasodilatation results in a poor surgical field. General anesthesia results in vasodilatation and the extent of the vasodilatation is to a certain extent dependent upon the type and quantity of inhalational agent used.⁶ Halothane gives significant vasodilatation and should not be used.⁶ Isoflurane and sevoflurane produce less vasodilatation but if they are used to deepen the level of anesthesia with the intention of lowering the blood pressure, significant vasodilatation can occur.⁶ Total intravenous anesthesia (TIVA) is usually given by utilizing a constant infusion of propofol. Propofol induces anesthesia by enhancing the action of GABA neurotransmitter on the GABA receptor, which allows the chloride channels to be opened causing hyperpolarization and reduced excitability of the cell.¹³ Propofol is short acting and needs to be administered as a constant infusion. Although it does depress the heart, this response is not dose-dependent and increasing the infusion rate of propofol will not result in an increasing suppression of pulse rate and cardiac output. It, however, does not affect the muscle tone of the prearteriolar and precapillary sphincters and does not cause vasodilatation and increased bleeding. This allows inhalational agents to be avoided. If bleeding during ESS continues to be problematic despite the patient receiving TIVA, other drugs such as β -blockers or clonidine can be added. In a recent study in our department, we performed a randomized controlled single-blinded (to the surgeon) study using TIVA and isoflurane. This study showed that the surgical fields were better if TIVA was used.¹⁴ All other factors were kept constant during the surgery. The pulse rate, when analyzed independently, again correlated to the surgical field, emphasizing the importance of the pulse rate on the surgical field. Some anesthetists are uncomfortable using TIVA as it can be difficult to judge the depth of anesthesia so it is a good idea to discuss the merits of use of TIVA with the anesthetist before surgery. Our protocol does not use a muscle relaxant. The remifentanyl

infusion sufficiently depresses the patient's respiration and allows the patient to be ventilated during the procedure. However, should the propofol become disconnected or infusion rate be inappropriate, then the patient wakes up and, because the patient is not paralyzed, it is obvious to all that the TIVA is no longer working.

β -Blockers

If vasodilatation occurs during general anesthesia the body attempts to compensate for this reduced venous return and low cardiac output by increasing the heart rate in an attempt to improve the cardiac output.^{3,4,6} In a seminal paper, Boesak and van der Merwe showed that vasodilatation induced by sodium nitroprusside caused a significant worsening in the surgical field despite the lowered blood pressure.³ What they also showed was that esmolol, a highly selective β_1 β -blocker, improved the surgical field with a much smaller drop in blood pressure.³ Esmolol is a short-acting cardioselective β adrenergic receptor-blocking drug that has a fast onset and short half-life. In contrast to a drug such as sodium nitroprusside, which although effectively lowering the blood pressure results in a compensatory increase in heart rate, esmolol is highly effective at depressing cardiac output and results in a slowing of the pulse rate despite a fall in blood pressure.⁶ Esmolol is given by a constant IV infusion and has a very short half-life (around 3 minutes) so its effect can be closely controlled. Although this can be a very worthwhile maneuver, it is a very expensive drug and there is some resistance (based on cost) against using it as a regular or routine part of ESS anesthesia. The expense of this drug stimulated our department to conduct a double-blind placebo controlled prospective study in the effects of metoprolol taken orally 20 minutes before general anesthetic, as compared to a vitamin B placebo.² This study showed that patients who received the β -blocker (metoprolol) had a significantly lower pulse rate (mean of 59) than the placebo group (mean of 69). There was no significant difference in blood pressure or surgical fields in the two groups. However, what was interesting was the significant correlation between heart rate in the overall patient group with surgical grade.² Thus, irrespective of whether a β -blocker is given to the patient, if the heart rate of the patient can be kept below 60 beats per minute, the surgical field was usually good.² Therefore, we recommend the use of a β -blocker (atenolol, metoprolol, or esmolol) in patients who at induction of anesthesia have a pulse rate significantly above 60 beats per minute and who do not have a contraindication (such as asthma) as a worthwhile manipulation that can improve the surgical field. However, asthma is a common comorbidity in patients with chronic sinusitis and alternatives are needed. In this group of patients we use clonidine.

Clonidine

Clonidine is a centrally active alpha agonist that initially results in an elevation of blood pressure before depressing the cardiac output by inhibiting the central cardiac regulatory

mechanism. It should be used with caution and should be given in small increments, as the effect is not easily reversible. It also results in mild postoperative sedation and its effects on the blood pressure are usually seen in the initial few hours after surgery. This is beneficial for the majority of patients as this mild hypotension allows the small blood vessels in the nose to coagulate with a reduced chance of postoperative epistaxis. There are now good studies in the literature that show that patients in whom clonidine has been used have significantly better surgical fields than those who do not. I therefore highly recommend the use of clonidine as part of the anesthetic technique to control MAP.

◆ Additional Maneuvers for Optimizing the Surgical Field in ESS

Suction Bipolar Cautery* of Isolated Bleeding Areas

It is common to see isolated bleeding vessels in the surgical field during ESS. These result from the transection of small blood vessels and may continue to ooze into the surgical field, significantly adding to the volume of blood that may obscure the surgical field.⁴ In addition, such an ooze may obscure the end of the endoscope requiring either the endoscope scrubber to be used or the endoscope to be removed from the nose to be cleaned. If the axillary flap approach to the frontal recess is used (Chapter 7), the cut mucosal edge may bleed and this can be controlled by the use of the suction bipolar cautery. Other common areas where bleeding is seen are the posterior region of the maxillary sinus, the sphenopalatine region of the lateral nasal wall, and from the anterior wall of the sphenoid below its ostium. The suction bipolar allows the bleeding vessels to be accurately identified and cauterized. Not having to remove the instrument from the nose after the suction clears the blood allows for identification of the bleeding point, which is a significant advantage of this instrument (Fig. 2.3).

The Anatomy of the Greater Palatine Canal and Local Anesthetic Infiltration of the Pterygopalatine Fossa

Injection of local anesthetic into the pterygopalatine fossa does improve the surgical field.^{15,16} The maxillary artery and

its terminal branches make up the main blood supply of the nose. There are two approaches; the less reliable approach is direct infiltration into the region of the sphenopalatine foramen. The needle is introduced just under the posterior end of the middle turbinate. Sometimes the needle can be felt to slip into the sphenopalatine foramen but in most cases location of the foramen is difficult and the injection is given into the general region of the foramen. This should cause vasospasm of the vessels exiting the foramen. However, because the foramen is not easily located, the resulting vasoconstriction achieved may not be as great as injecting the pterygopalatine fossa through the greater palatine canal.

The second more reliable approach is to inject the pterygopalatine fossa through the greater palatine foramen and canal. First, the greater palatine foramen needs to be located on the hard palate (Fig. 2.4). The greater palatine foramen is located just anterior to the posterior edge of the hard palate opposite the second molar tooth.¹⁶ It is usually halfway between the tooth and the midline of the hard palate. The opening of the foramen into the canal is funnel-shaped and the canal is angled at about 45 degrees to the hard palate.

In a cadaver study performed in our department to evaluate the anatomy of the greater palatine canal, 20 cadaver heads were CT scanned in the axial plane at 0.5 mm.¹⁶ Parasagittal reconstructions were performed in the plane of the greater palatine canal. The length of the canal and depth of the soft tissue overlying the canal were measured. In addition, needles were bent at 10, 20, and 30 mm and inserted into the greater palatine canal prior to CT scanning to demonstrate the degree of penetration into the pterygopalatine fossa in four cadavers (Fig. 2.5).

This was done to ascertain the likelihood of damage to the contents of the fossa (branches of the maxillary nerve, maxillary artery, and pterygopalatine ganglion) and the orbit. Note that the bend in the needle stops at the soft tissue overlying the hard palate and that this soft tissue had a mean thickness of 6.9 mm (95% CI = 6.2–7.6) (Fig. 2.6). The mean length of the greater palatine canal was 18.5 mm (95% CI = 17.9–19.1) and the mean height of the pterygopalatine fossa was 21.6 mm (95% CI = 20.7–22.5).¹⁶ Therefore, to perform an effective infiltration of the pterygopalatine fossa, the needle should be bent at 25 mm from the tip at an angle of 45 degrees.¹⁶ This will result in the tip of the needle just penetrating the pterygopalatine fossa without putting any of the contents of the fossa at risk.¹⁶

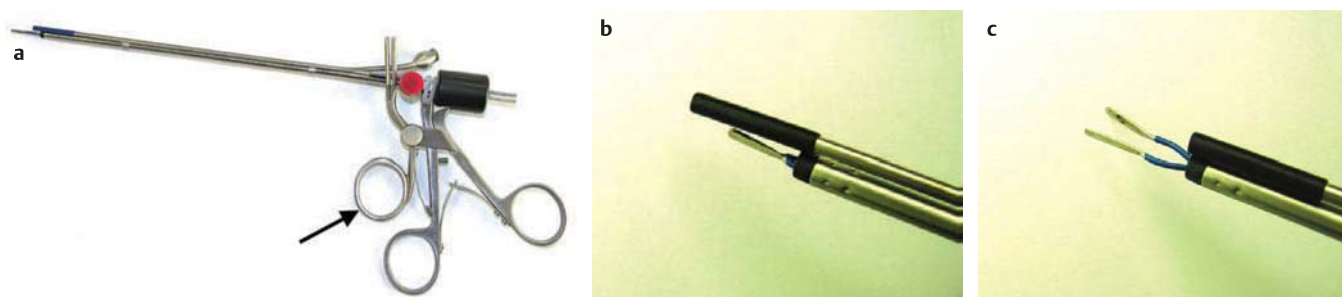


Fig. 2.3 (a) The suction bipolar is in the normal position. (b) The suction is extended beyond the bipolar paddles. When the manipulating lever (black arrow) in (a) is relaxed the suction retracts behind the bipolar paddles (c).

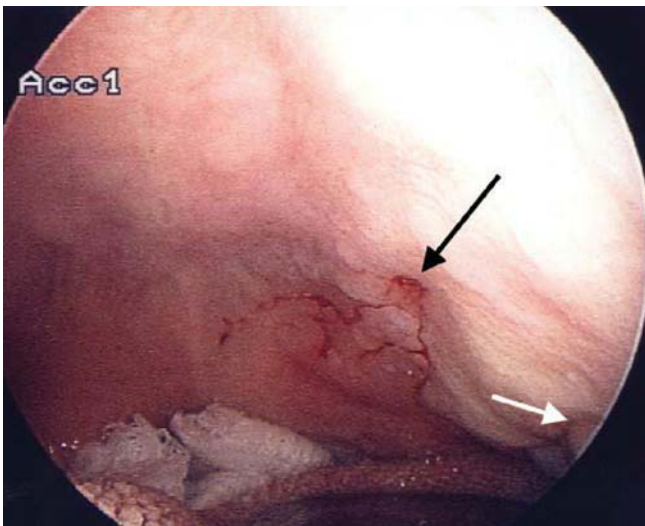


Fig. 2.4 Blood staining can be seen from where the needle was introduced into the greater palatine canal (*black arrow*) of the left hard palate. The second molar tooth is marked with a *white arrow*.

The greater palatine canal has an hourglass shape, dilating as it enters the pterygopalatine fossa. This funnel-shaped entrance into the greater palatine canal means that it can be difficult to determine exactly where the pterygopalatine fossa ends and the greater palatine canal begins (*white arrow*) (**Fig. 2.6**).

The easiest way to locate the greater palatine foramen is by palpating the palate with the finger. This is performed by placing a tongue depressor in the mouth and holding down the tongue, then passing a finger and the endoscope into the mouth together. The finger first locates the posterior free edge of the hard palate and then slides anteriorly over this ridge onto the hard palate. The foramen should be felt as a depression directly anterior to the free edge about midway between the second molar tooth and the midline of the palate. Visualize the finger palpating the foramen on the monitor and identify the spot on the palate as the finger is withdrawn from the mouth. With the needle bent at 25 mm and at a 45-degree angle, insert the needle into the spot that you had visually marked on the palate. If the needle strikes bone then a small amount of lidocaine is infiltrated, the needle is withdrawn, and an adjacent spot is tried. The assumption is that the needle had just missed the foramen and that a slight adjustment needs to be made before the foramen is located. If repeated attempts to introduce the needle fail, then the landmarks for the foramen (the midpoint between the second molar tooth and midline of the palate) are reassessed and the finger and endoscope are replaced into the mouth and the foramen relocated. The needle is reintroduced until the foramen is located by the needle advancing into the greater palatine canal without any resistance up to the bend in the needle. After aspirating (to ensure that the needle is not in a blood vessel), the pterygopalatine fossa is infiltrated with 2 mL of 2% lidocaine and 1:80,000 adrenaline.

Our department has conducted a double-blind randomized controlled trial in which the effects of local anesthetic and adrenaline infiltration of the pterygopalatine fossa were

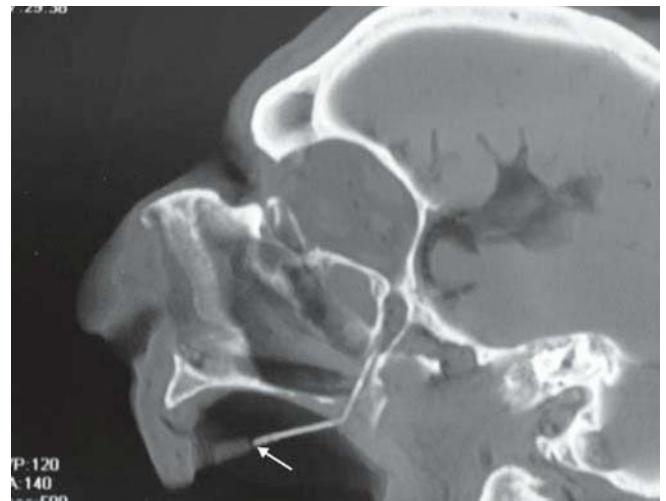


Fig. 2.5 Cadaver with needle (*white arrow*) bent at 20 mm and inserted into the greater palatine canal after which the CT scan was performed.

assessed on the surgical field in 55 patients.¹⁷ To be included in the study the patient required bilateral ESS with similar procedures being performed bilaterally. A surgeon not involved in the surgery randomly infiltrated one fossa transorally so that the operating surgeon would not be aware of which side had been infiltrated. The surgeon then alternated the surgery on the patient and assessed the surgical field on each side. Statistical analysis showed that the side that had received the pterygopalatine fossa injection had significantly better surgical field (mean surgical grade of 2.59) than the control side (mean surgical grade of 2.99; $p < 0.01$).¹⁷

◆ General Guidelines for the Maneuvers for Improving the Surgical Field

The ideal surgical field is grade 2 on the Boezaart scale and grades 1–4 on the Wormald scale. However, the majority of

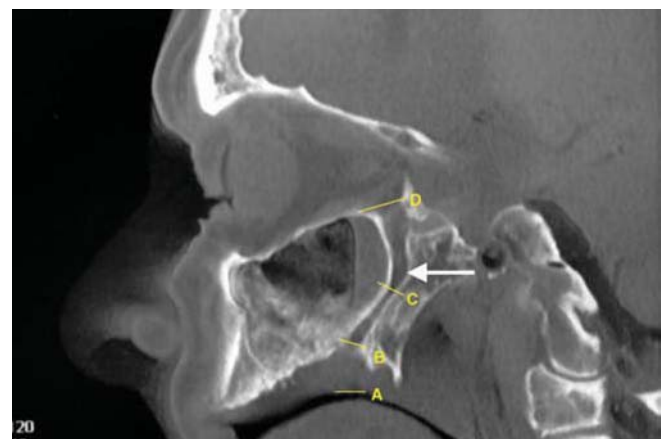


Fig. 2.6 The soft tissue measurement was from (a) to (b), the greater palatine canal from (b) to (c), and the height of the pterygopalatine fossa from (c) to (d). The funnel-shaped opening of the greater palatine canal into the pterygopalatine fossa is indicated with a *white arrow*.

our patients fluctuate between grade 2 and 3 on the Boezaart scale and 2–6 on the Wormald scale. Operating in more bloody conditions can be aided by the use of suction dissection instruments* (see Chapter 1) such as the suction curette* and suction Freers*. These instruments allow the blood to be cleared from the surgical field during the dissection and obviate the need to change from a dissecting instrument to a suction in order to clear the surgical field.

Surgical Field Change from Boezaart Grade 3 to Grade 4 or 5

Please note surgery should not be performed if the surgical field is grade 5 or Wormald grade 8–10.

- ◆ Check positioning of the patient
- ◆ Check that you have properly infiltrated the lateral wall of the nose with lidocaine and adrenalin
- ◆ Place neuropatties soaked with cocaine and adrenaline in the surgical field
- ◆ Check the patient's pulse rate and, if greater than 60, ask the anesthetist to adjust this to below 60 (using β -blockers if not contraindicated)
- ◆ If the patient is hypertensive, ask the anesthetist to bring the mean blood pressure down to around a mean of 65 mm Hg without increasing the inhalational agent (consider the use of a β -blocker or clonidine).

Re-check Your Surgical Field

- ◆ If there is a specific bleeder, cauterize it with the suction bipolar.*
- ◆ If the bleeding is emanating from the posterior region of the nasal cavity, consider replacing the neuropatties and performing a pterygopalatine fossa block.
- ◆ If bleeding is still not controlled or is coming from the anterior aspects of the nose, then consider asking the anesthetist to further lower the pulse rate with small incremental doses of clonidine. Remember to stay within the safe range of MAP (>60 mm Hg^{6,11,12}), especially when considering the age of the patient and the previous mean blood pressure of the patient. If the patient was known to suffer from hypertension this figure should be higher.
- ◆ Consider changing patient from inhalational anesthesia to TIVA.

References

1. Stankiewicz JA. Complications of endoscopic intranasal ethmoidectomy. *Laryngoscope* 1987;97(11):1270–1273
2. Nair S, Collins M, Hung P, Rees G, Close D, Wormald PJ. The effect of beta-blocker premedication on the surgical field during endoscopic sinus surgery. *Laryngoscope* 2004;114(6):1042–1046
3. Boezaart AP, van der Merwe J, Coetzee A. Comparison of sodium nitroprusside- and esmolol-induced controlled hypotension for functional endoscopic sinus surgery. *Can J Anaesth* 1995;42(5 Pt 1):373–376
4. Boezaart AP, van der Merwe J, Coetzee AR. Re: Moderate controlled hypotension with sodium nitroprusside does not improve surgical conditions or decrease blood loss in endoscopic sinus surgery. *J Clin Anesth* 2001;13(4):319–320
5. Mortimore S, Wormald PJ. Management of acute complicated sinusitis: a 5-year review. *Otolaryngol Head Neck Surg* 1999;121(5):639–642
6. van Aken H, Miller ED. *Deliberate Hypotension*. In: Miller RD, ed. *Anesthesia*. Vol. 2. New York, NY: Churchill Livingstone; 1994:1481–1503
7. Shaw CL, Dymock RB, Cowin A, Wormald PJ. Effect of packing on nasal mucosa of sheep. *J Laryngol Otol* 2000;114(7):506–509
8. Sieskiewicz A, Olszewska E, Rogowski M, Grycz E. Preoperative corticosteroid oral therapy and intraoperative bleeding during functional endoscopic sinus surgery in patients with severe nasal polyposis: a preliminary investigation. *Ann Otol Rhinol Laryngol* 2006;115(7):490–494
9. Condon HA. Deliberate hypotension in ENT surgery. *Clin Otolaryngol Allied Sci* 1979;4(4):241–246
10. Cardesin A, Pontes C, Rosell R, et al. A randomised double blind clinical trial to compare surgical field bleeding during endoscopic sinus surgery with clonidine-based or remifentanyl-based hypotensive anaesthesia. *Rhinology* 2015;53(2):107–115
11. Ha TN, van Renen RG, Ludbrook GL, Valentine R, Ou J, Wormald PJ. The relationship between hypotension, cerebral flow, and the surgical field during endoscopic sinus surgery. *Laryngoscope* 2014;124(10):2224–2230
12. Ha TN, van Renen RG, Ludbrook GL, Wormald PJ. The effect of blood pressure and cardiac output on the quality of the surgical field and middle cerebral artery blood flow during endoscopic sinus surgery. *Int Forum Allergy Rhinol* 2016;6(7):701–709
13. Sonner J, Zhang Y, Stabernack C, Abaigar W, Xing Y, Laster M. GABAA receptor blockade antagonizes the immobilizing action of propofol but not ketamine or isoflurane in a dose-related manner. *Anesth Pharm* 2003;96(3):706–712
14. Wormald PJ, van Renen G, Perks J, Jones JA, Langton-Hewer CD. The effect of the total intravenous anesthesia compared with inhalational anesthesia on the surgical field during endoscopic sinus surgery. *Am J Rhinol* 2005;19(5):514–520
15. Wormald PJ, Wee DTH, van Hasselt CA. Endoscopic ligation of the sphenopalatine artery for refractory posterior epistaxis. *Am J Rhinol* 2000;14(4):261–264
16. Douglas R, Wormald PJ. Pterygopalatine fossa infiltration through the greater palatine foramen: where to bend the needle. *Laryngoscope* 2006;116(7):1255–1257
17. Wormald PJ, Athanasiadis T, Rees G, Robinson S. An evaluation of effect of pterygopalatine fossa injection with local anesthetic and adrenalin in the control of nasal bleeding during endoscopic sinus surgery. *Am J Rhinol* 2005;19(3):288–292

3 Imaging in Endoscopic Sinus Surgery

◆ Introduction

It is fortunate that the development of endoscopic sinus surgery (ESS) has coincided with major advances in computed tomography (CT) scanning technology. Before CT scanning was available, the extent of sinus disease and anatomy of the nose and sinuses were assessed on plain X-rays. Plain X-rays are no longer used in this role as they do not provide sufficient anatomical detail or accurate information on the extent of nasal and sinus pathology. The CT scan has allowed the detailed anatomy of the sinuses to be evaluated and, in this textbook, CT scans are used extensively to reconstruct the anatomy of the sinuses, thereby enabling a surgical plan to be made before surgery begins. The surgical philosophy of this textbook is underpinned by the availability of high quality CT scans in three planes.

◆ Computed Tomography Scans

The Value of Scans in Three Planes

CT scans are used as an aid for both the diagnosis of chronic sinusitis and for the planning of the surgery. However, there is a significant incidence of mucosal abnormalities seen in completely asymptomatic patients.¹ Thus, it is important that the patient has undergone adequate medical treatment for the nasal and sinus condition before a CT scan of the sinuses is performed.² The coronal scan is the primary scan used to assess the anatomy of the sinuses.³ These scans should be sufficiently close together so that an identified cell can be followed from one slice to the next. This allows a three-dimensional image of the anatomy to be reconstructed from the scans.⁴⁻⁶ The axial scan is of particular value in determining the drainage pathway of the frontal sinus. This is important when deciding where the curette or probe is going to be slid during the dissection of the frontal recess. Our department published a study evaluating the value of the

parasagittal scan in assessing the frontal recess and in the understanding and planning of the surgery.⁷ We found that the parasagittal scan significantly improved the surgeon's ability to assess the frontal recess and improved the understanding of the anatomy by a mean of 57% on a 10-point visual analog scale. The parasagittal scan also altered the surgical plan for the patient in over 50% of patients studied. We therefore recommend that the all patients undergoing ESS have a high definition helical 64 multislice CT scan of the sinuses with the scans presented in all three planes. An example of the quality of the CT scans that should be expected using this protocol is shown in **Fig. 3.1**.

Disclaimer

Software that allows the CT scan to be simultaneously viewed in all three planes and that allows the anatomy of the cells to be reconstructed was developed in conjunction with Scopis®. The author received royalties from the sale of this software.

Scanning Protocol

Good quality CT scans are critical to the ability of the surgeon to reconstruct the anatomy and drainage pathways of the sinuses. Ideally, images should be in the coronal, axial, and parasagittal plane and should be relatively close together so that a cell can be followed from one scan to the next. Our current CT scan imaging protocol on a 64 multislice CT helical scanner requires scans to be performed in the axial plane at 0.5-mm to 1-mm intervals with coronal and parasagittal reconstruction. Images in all planes are printed for the surgeon and available for digital download and used on the Scopis software for viewing and detailing of the anatomy (see disclaimer). The windows of the scan are set at between 1500 and 2000 with a center of +100 to +300 for highest bony definition. If there is a suspicion of fungal sinus disease, the

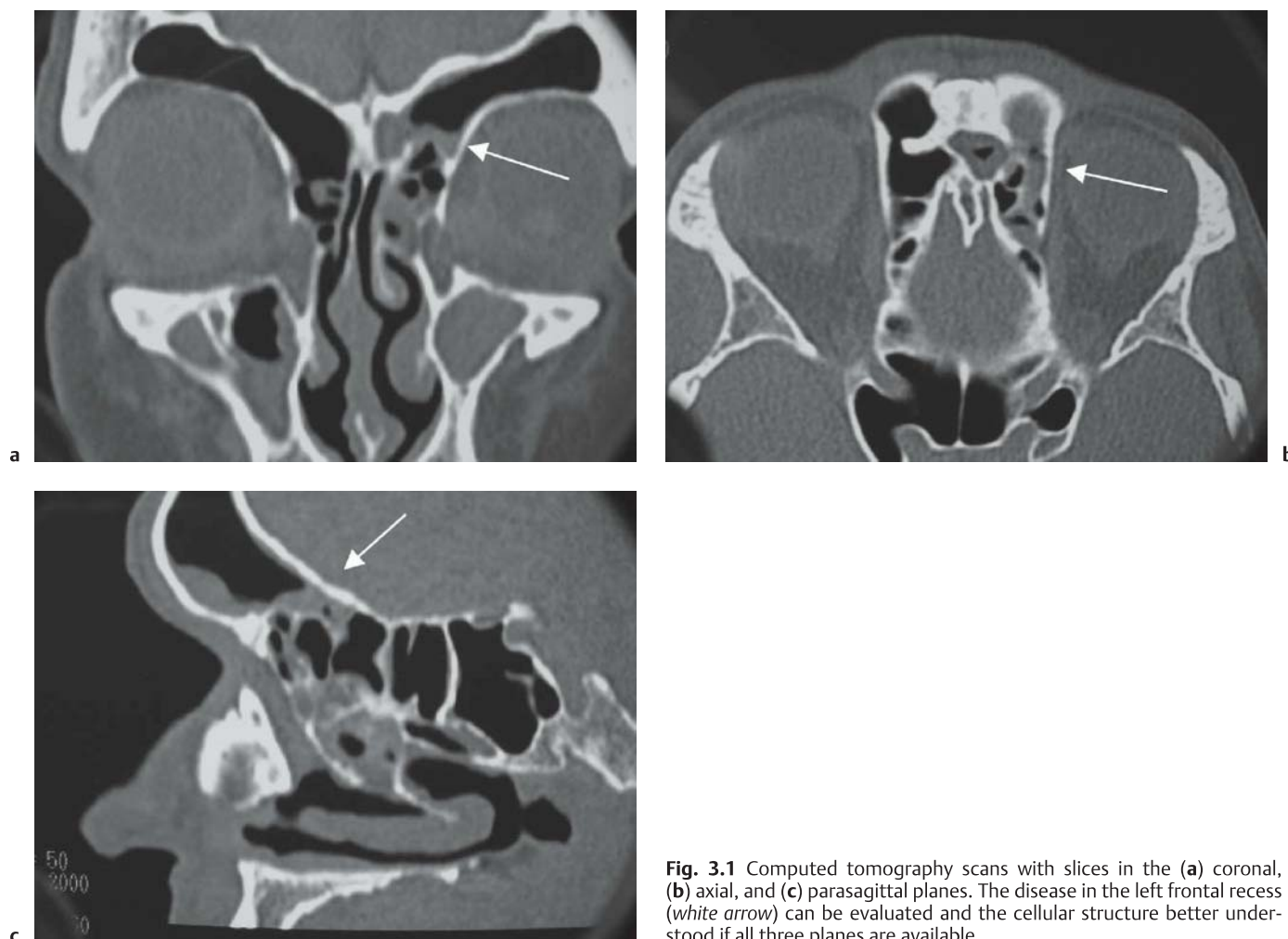


Fig. 3.1 Computed tomography scans with slices in the (a) coronal, (b) axial, and (c) parasagittal planes. The disease in the left frontal recess (*white arrow*) can be evaluated and the cellular structure better understood if all three planes are available.

window settings are changed to soft tissue settings. This allows the opacified sinuses to be assessed for double densities that are often present in chronic fungal sinus disease.

Three-Dimensional Views and the Concept of Building Blocks

Some CT scanners have software where cursors can be moved through a series of scans in one plane while at the same time the views of where the cursor is in the other planes is simultaneously displayed. Software that does the same thing can be purchased independently if not available on the scanner. Scopis software is available for download (<http://planning.scopis.com>) and is suitable for both PCs and MACs. It allows DICOM images from CT scanners to be loaded and will create images in all three planes with movable crosshairs. In addition, all computer-aided surgical (CAS) systems also have this facility. With these systems, the CT scans can be scrolled in a particular plane and the other views change depending upon where the cursor is placed on the scan being viewed. Scopis software is able to draw a building block over each cell and place a drainage

pathway along the frontal sinus drainage pathway. This allows the surgeon not only to fully understand the anatomy of the frontal recess but also to carefully plan each surgical step of the dissection. An example of such a reconstruction is shown in **Fig. 3.2**.

A central theme throughout this book is the utilization of high quality CT scans in three different planes to build a three-dimensional picture of the anatomy of the sinuses. In this book, I use Scopis software to place a building block on each cell. **Fig. 3.2** shows a red building block placed on the agger nasi cell. Note how each corner of the building block has a circle in each of the planes. The surgeon chooses which plane would be best to manipulate the block and then grabs these corners to change the block in one plane. Once this is done, the circles on the corners of the other blocks disappear but the sides of the block can still be manipulated. In **Fig. 3.3** the axial plane block has been manipulated to better fit the CT scan. In **Fig. 3.4** the supra agger cell (*green box*) has been manipulated in the parasagittal plane. In **Fig. 3.5** the frontal septal cell (*blue box*) has been manipulated in the axial plane and in **Fig. 3.6** the supra bulla cell (*pink box*) has been manipulated in the parasagittal plane. The final cell of the frontal recess (*light blue box*) completes the anatomical

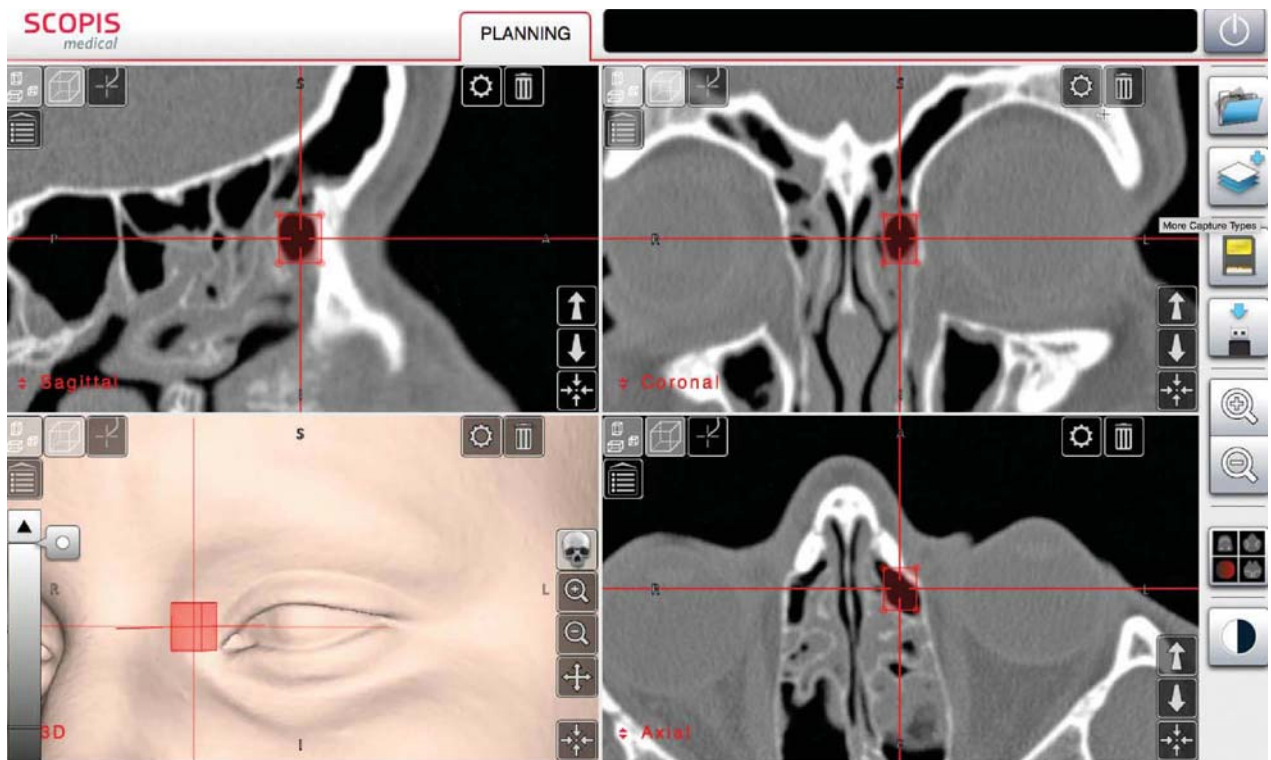


Fig. 3.2 The red building block is placed over the left agger nasi cell. In all three planes the corners of the building block are circles. The surgeon can choose which plane to manipulate the corners.

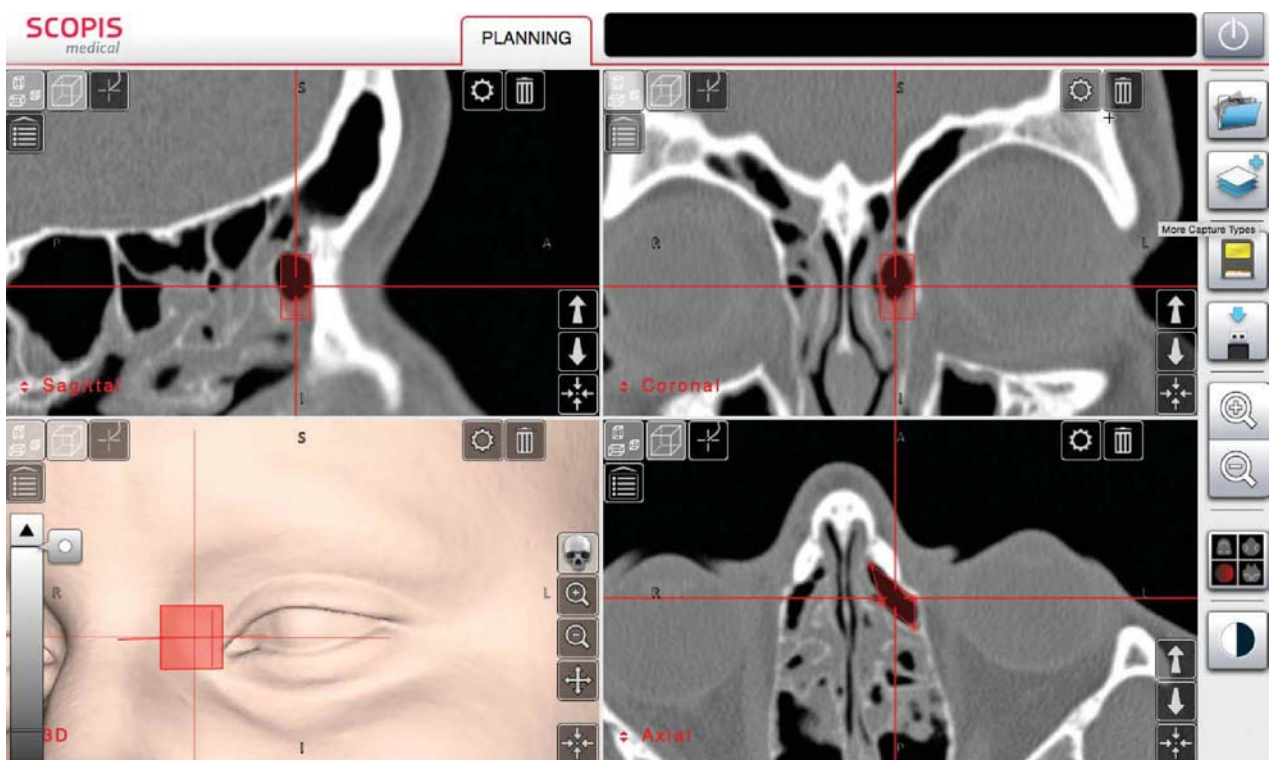


Fig. 3.3 The building block has been manipulated in the axial plane so the circles have disappeared in the other planes. The sides of the blocks in the other planes can be manipulated but only the corners in the axial plane.

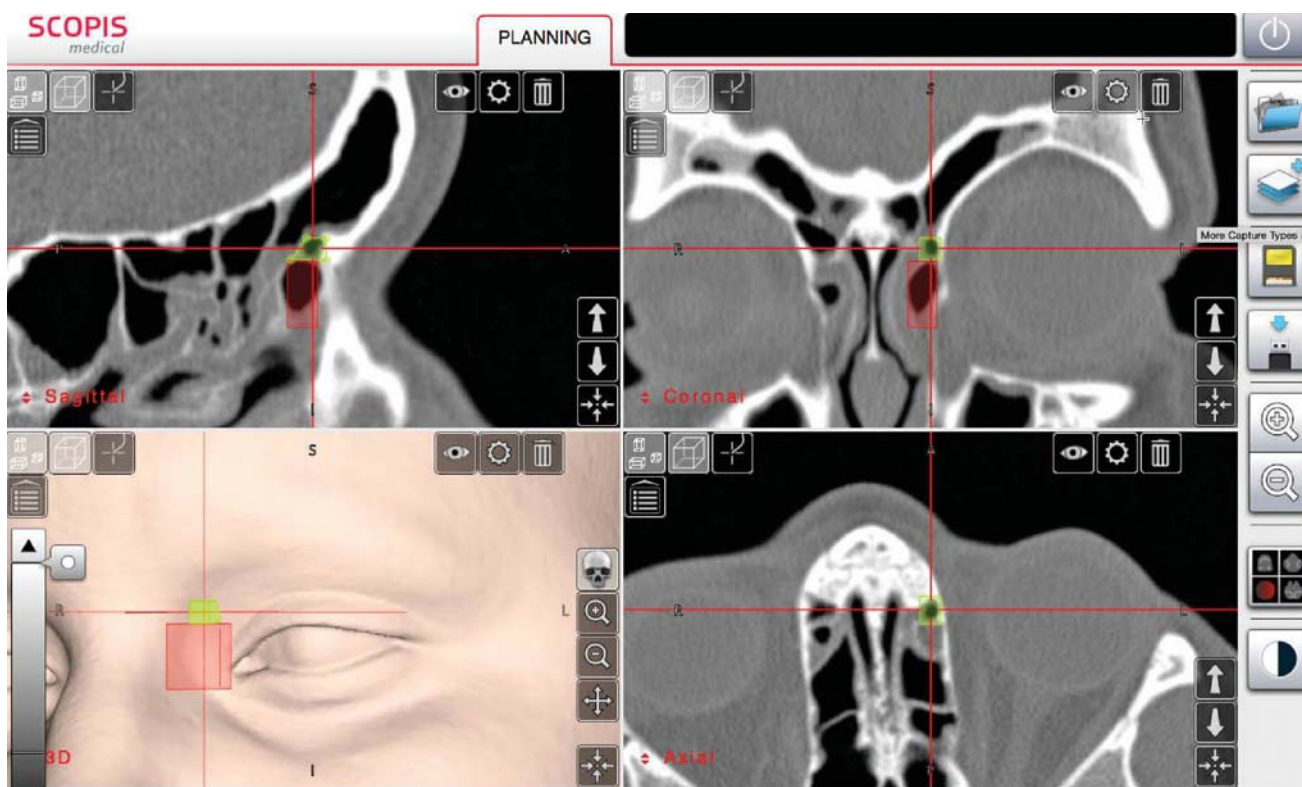

Fig. 3.4 The green building block has been placed over the supra agger cell and manipulated in the parasagittal plane.

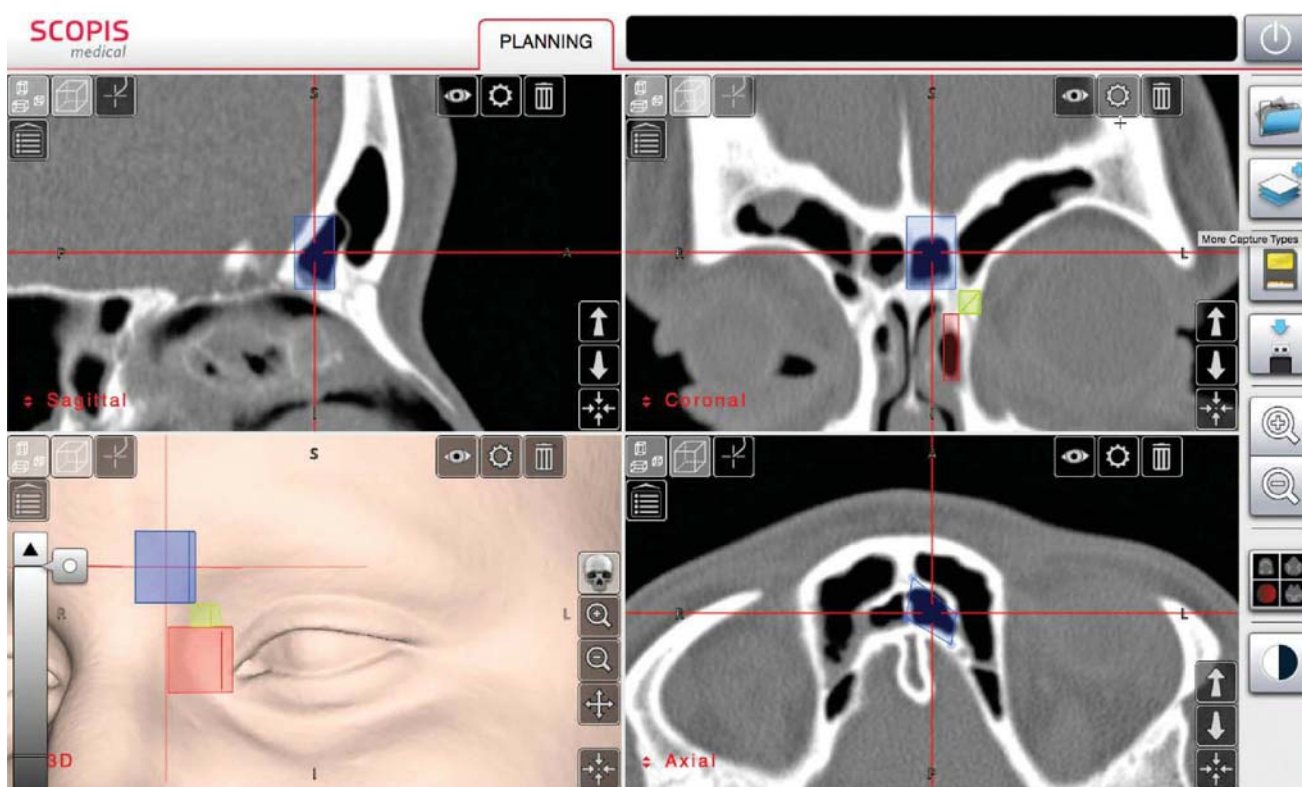


Fig. 3.5 A blue block has been placed over the frontal septal cell and has been manipulated in the axial plane.

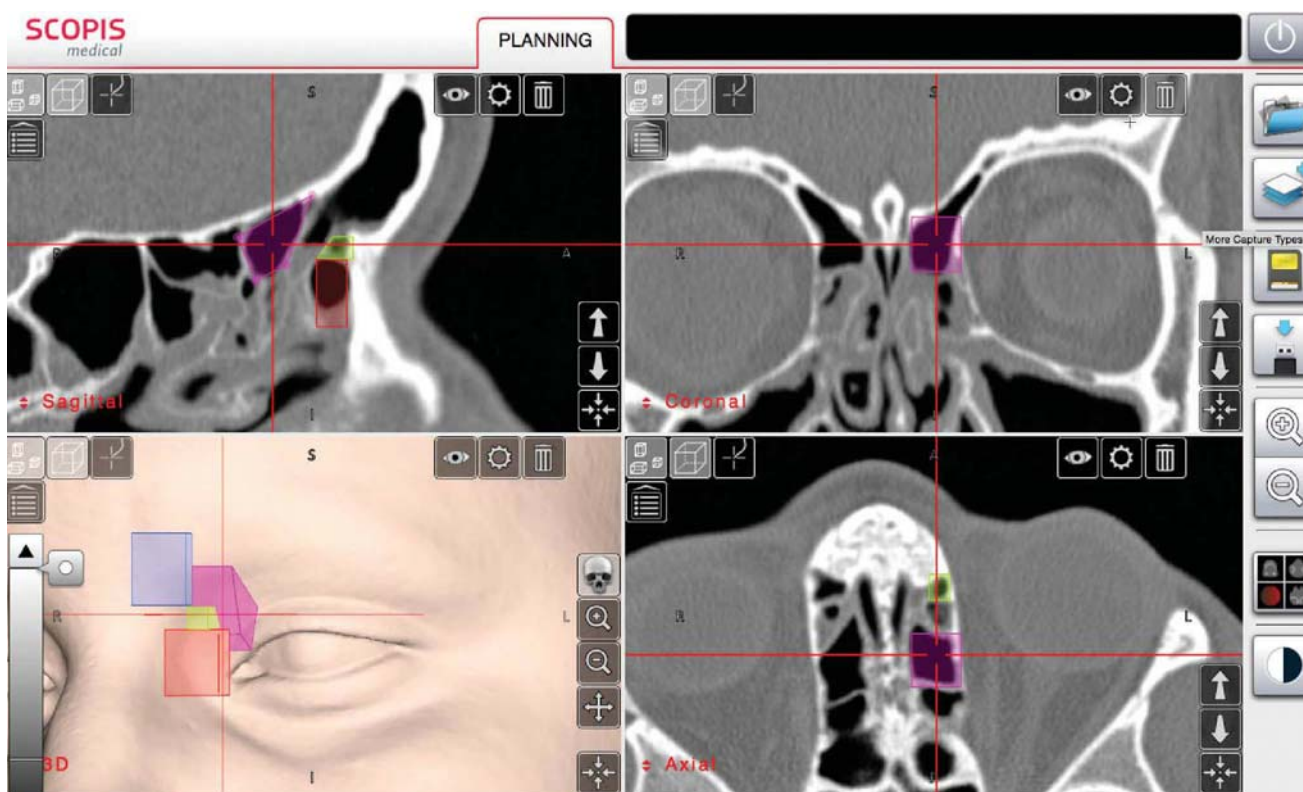

Fig. 3.6 The pink block has been placed over the supra bulla cell and has been manipulated in the parasagittal plane.

configuration of this patient's frontal recess (**Fig. 3.7**). In the bottom left box of **Fig. 3.7**, all the cells can be seen that make up the anatomy of the frontal recess. **Fig. 3.8** shows the frontal sinus drainage pathway that has been placed among the cells. Note how the drainage pathway passes lateral to the frontal septal cell but posteromedial to the supra agger cell and agger nasi cell and in front of the supra bulla cell and bulla ethmoidalis. This ability to understand both the cells and the frontal drainage pathway is especially important in understanding the anatomy of the frontal recess (Chapter 6). After completion of the frontal recess, the process can be repeated in the posterior ethmoids and sphenoid (Chapter 8). The concept of three-dimensional anatomical reconstruction using building blocks to re-create the anatomical formation in the frontal recess and posterior ethmoids and then to surgically establish the drainage pathways is the central theme of this textbook.

◆ Magnetic Resonance Imaging Scans

Magnetic resonance imaging (MRI) scans are not routinely used for the assessment of patients undergoing ESS as they do not provide bony definition. In addition, MRI scans are very sensitive to mucosal thickening of the nasal or sinus mucosa (especially of a vascular region such as the inferior turbinate). Normal mucosa may enhance and in some patients even appear pathological even though it is normal.

However, the MRI scan can be very useful in a number of situations. We routinely request a MRI scan in patients who have previously undergone an osteoplastic flap with obliteration who have ongoing symptoms.^{8,9} In these patients, the MRI can differentiate sepsis or mucocele formation from those with healthy fat in their obliterated frontal sinuses. All patients who have an intranasal tumor are assessed with an MRI scan.¹⁰ In these patients, we are primarily interested in whether an opacified sinus is filled with tumor or retained mucus and whether a breach or invasion of the dura or orbital periosteum has occurred. An example of the usefulness of a MRI in surgical planning is shown in **Fig. 3.9**. This patient had an adenocarcinoma with opacified frontal sinuses and right maxillary sinus on CT scanning. On the MRI, it can clearly be seen that the left frontal sinus and right maxillary sinus are filled with mucus not tumor.

Our protocol to assess these patients is to perform a T1-weighted fat saturation gadolinium-enhanced scan and a T2-weighted scan. The tumor enhances on the T1 gadolinium-enhanced scan but the fluid in the sinuses does not. If the T2-weighted scan is reviewed, fluid (mucus) usually enhances significantly. In scans (c) and (d) of **Fig. 3.9**, the lamina papyracea and skull base are eroded. However, it appears that the orbital contents have been pushed laterally by the tumor rather than the tumor invading into the orbit. In this patient both orbits were preserved and there was a good surgical plane between the tumor and the orbital periosteum. The tumor also appears to push the dura superiorly rather than eroding through the dura. Again, we were

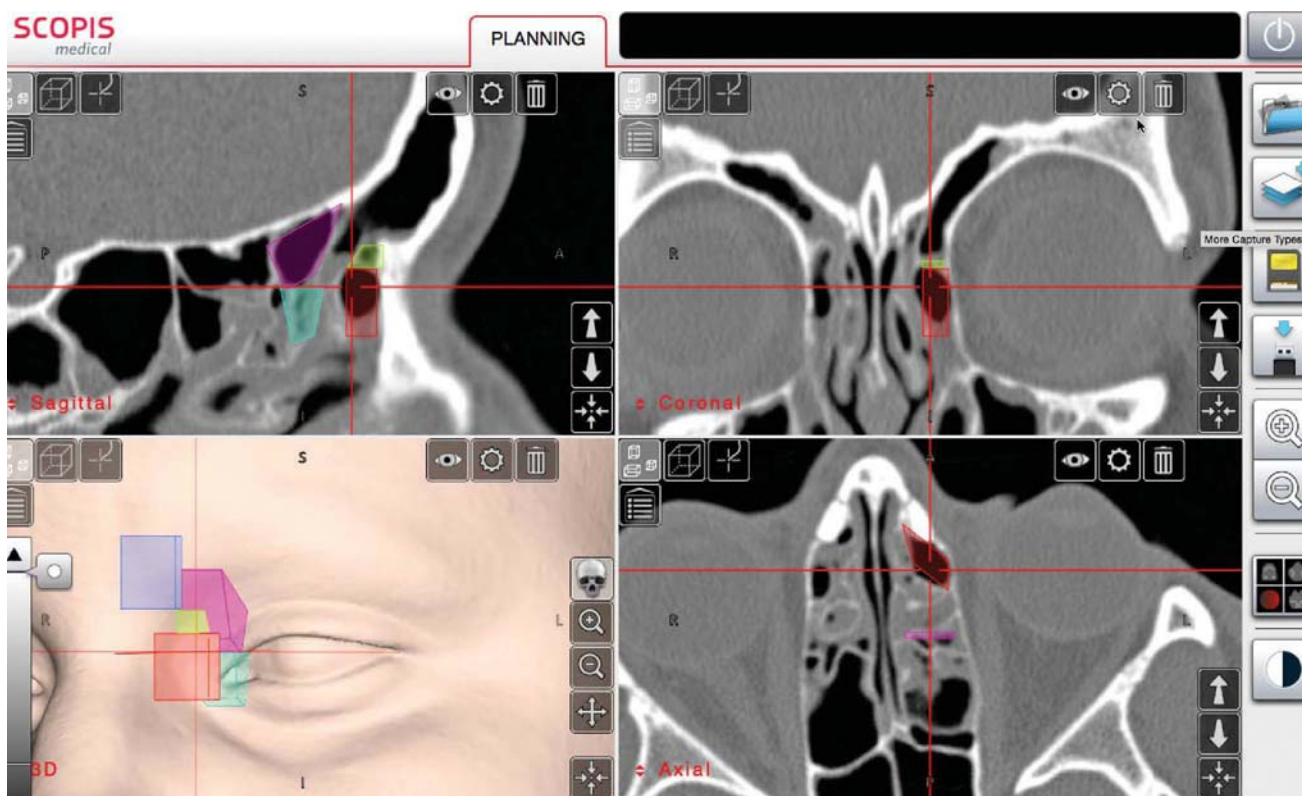


Fig. 3.7 The light blue block has been placed over the bulla ethmoidalis and manipulated in the parasagittal plane.

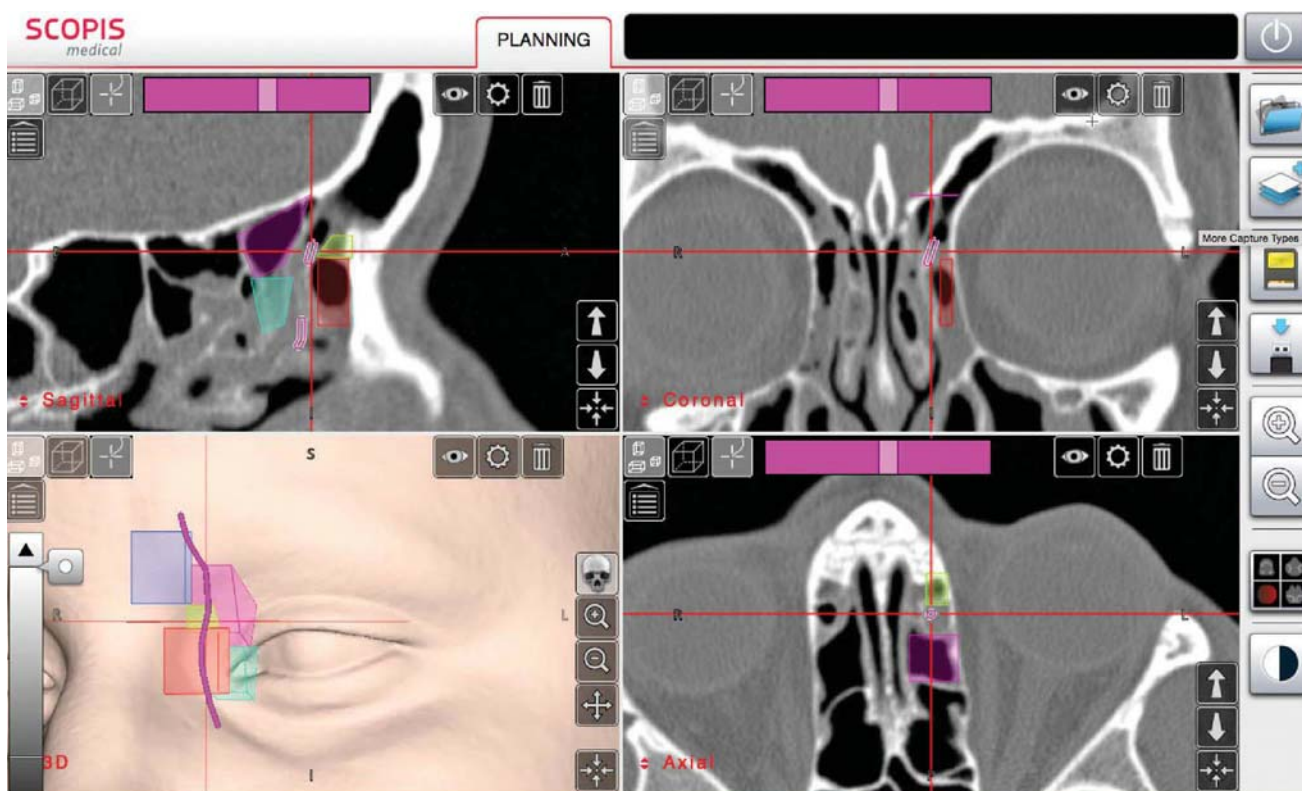

Fig. 3.8 The frontal sinus drainage pathway has been drawn in on the parasagittal plane and then its position checked and manipulated in the other planes until the pathway was correct.